

Ridge preservation and GTR with a xenograft and resorbable collagen membrane

Author Drs Mariana Baglivo, Hugo Campos, Ángel Miguel Carrasco, Andrés Pascual, Paul Levi & Prof José Nart

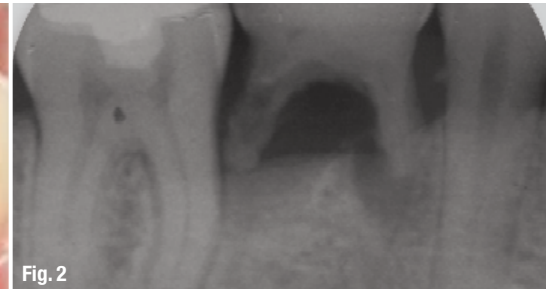
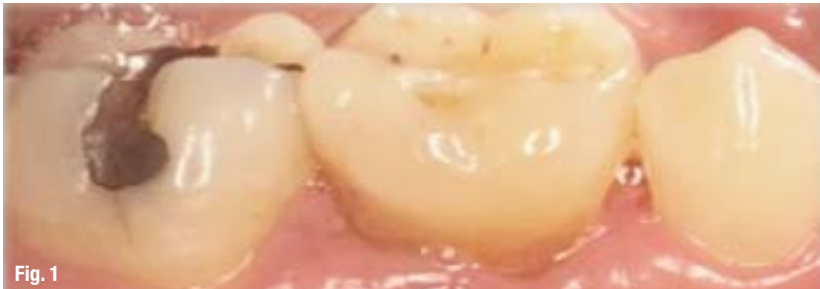

Fig. 1

Fig. 2

Figs. 1 & 2 The patient was referred for extraction of a right temporary mandibular second molar.

An adequate width and height of bone in an edentulous area is essential when placing an implant in order to obtain an ideal functional and an aesthetic prosthetic reconstruction following placement.

Dimensional alterations of the alveolar ridge (two-thirds) takes place during the first three months following extraction, and an average of 40% of original height and width is expected to be lost after three years (Lekovic *et al.* 1997; Schropp *et al.* 2003).

Figs. 3 & 4 Image of the combined two- and three-walled bony defect of 6 mm and 5 mm, and the fenestration of the buccal plate.

Histological investigations have described the healing of extraction sockets (Amler *et al.* 1960). Tooth extraction results in a loss of alveolar bone volume, both horizontally and vertically owing to resorption. The greatest amount of bone loss happens in the horizontal dimension and occurs on the facial aspect of the ridge. There is also a loss of vertical ridge height, which is most pronounced towards the buccal area. As alveolar bone is a tooth-dependent structure, the normal post-extraction healing is resorptive. Because the crest of the buccal bone is composed of bundle bone, this remodelling results in vertical reduction of the crest (Araújo & Lindhe 2005). The majority of the di-

The most predictable way to maintain the width, height and position of the alveolar ridges is to perform ridge preservation at the time of tooth extraction. This procedure requires an intra-socket osseous graft and the use of a membrane and should reduce the morphological changes in alveolar bone (Lekovic *et al.* 1998; Wang *et al.* 2004). In a six-month animal study, Araújo and Lindhe demonstrated that the placement of a biomaterial in an extraction socket may modify the remodelling and ridge resorption that occurs following tooth extraction. They observed that there was an average of 35% of ridge resorption in natural healing

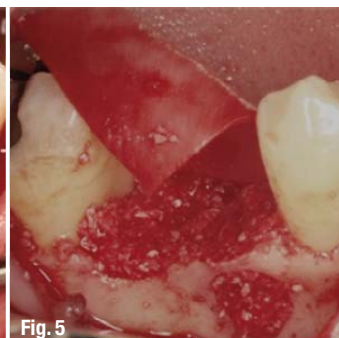
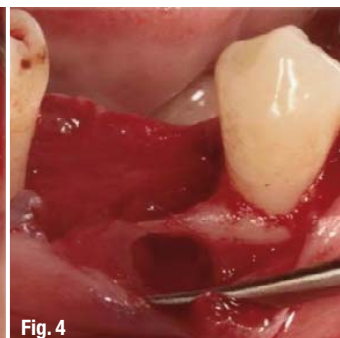
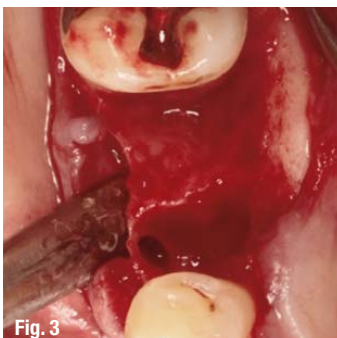


Fig. 3

Fig. 4

Fig. 5

Fig. 6

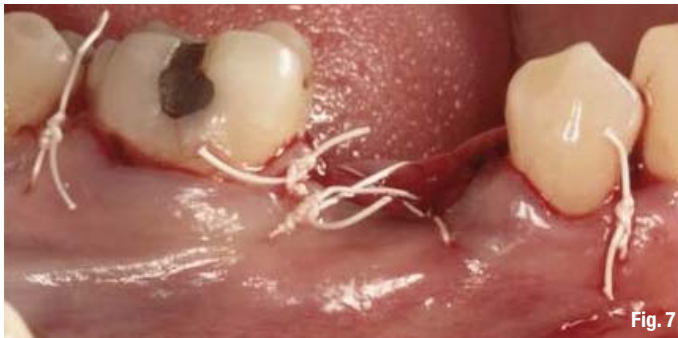

Fig. 7

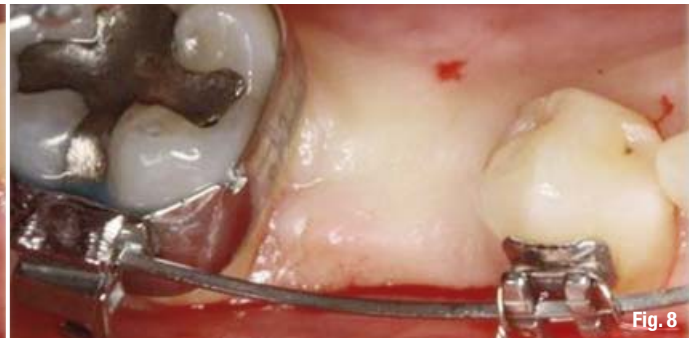

Fig. 8

and only 12% in the grafted sites (Araújo & Lindhe 2009).

The materials and the surgical techniques in use today simplify ridge preservation before implant placement and enable clinicians to ensure the functional and aesthetic outcome of the implants and subsequent restorations more predictably. Various natural and synthetic bone graft materials are available for the clinician to use for ridge preservation. Bone grafts in general are divided into four major categories: autogenous, allografts, xenografts and alloplasts. Although the gold standard is the autogenous graft, studies have proven the reliability and functionality of using either an allograft or xenograft, which avoids the creation of an additional surgical site for bone harvesting. In addition, there is rapid resorption of autogenous grafts, which is much slower with mineralised allografts or xenografts (Artzi *et al.* 2000; Vence *et al.* 2004; Irinakis 2006).

The use of barrier membranes has become a standard of care in guided bone regeneration and for alveolar ridge preservation and/or augmentation. The membrane excludes fast growing cells—epithelial and connective tissue cells—while enabling mesenchymal progenitor cells to proliferate and to differentiate into osteoblasts. When this surgical technique was established initially, membranes made of expanded polytetrafluoroethylene (ePTFE) were used. Although clinical and experimental studies found excellent treatment results using ePTFE membranes, wound healing complications with infection sequelae arose following the exposure of membranes. Therefore, clinicians and re-

searchers have advocated the use of bioabsorbable barrier membranes (Zellin *et al.* 1995). There are two main materials used to manufacture bioabsorbable membranes: collagen derived from an animal source and synthetic materials. The ability of collagen to promote progenitor cell adhesion, chemotaxis, homeostasis and physiological degradation, along with its ease of manipulation and low immunogenicity, make it an ideal barrier material (Rothamel *et al.* 2004).

Successful regeneration is possible, provided that cell exclusion and space maintenance prevails for the time needed for repopulation of the site with progenitor cells. This period may vary between three to 12 months for bone regeneration in edentulous areas. The structural integrity of implanted bioabsorbable barrier membranes needs to be preserved for an adequate period to allow maturation of the newly formed tissue under the membrane-protected space.

The purpose of the present case report is to evaluate clinically and histologically a ridge preservation using a xenograft and resorbable collagen membrane following tooth extraction.

_Case

A 40-year-old female patient was selected for this case report. Other than localised periodontal disease around a right temporary mandibular second molar, she had no systemic disease. The patient was referred for extraction of this molar. The reason for the extraction was type III mobility and the radiological image (Figs. 1 & 2).

Fig. 7 The flaps were replaced and were sutured without obtaining complete socket coverage.

Figs. 8 & 9 Clinical and radiographic view at six months following ridge preservation.

Fig. 10 Surgical re-entry for implant placement. Clinically, xenograft particles were well integrated into the alveolus, and the regenerated area is easily distinguished from the original bone tissue.

Figs. 11 & 12 A bone biopsy specimen was harvested in the area previously regenerated using a bone trephine drill.

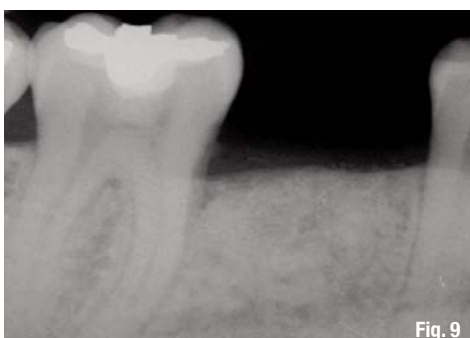

Fig. 9

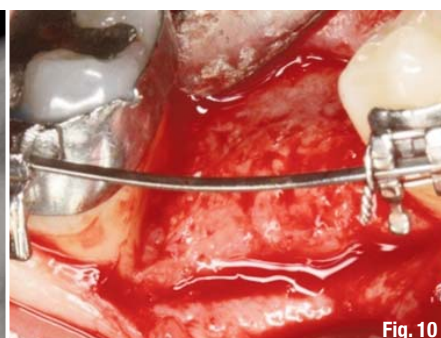


Fig. 10

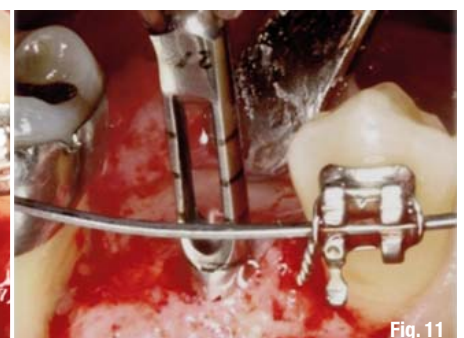


Fig. 11

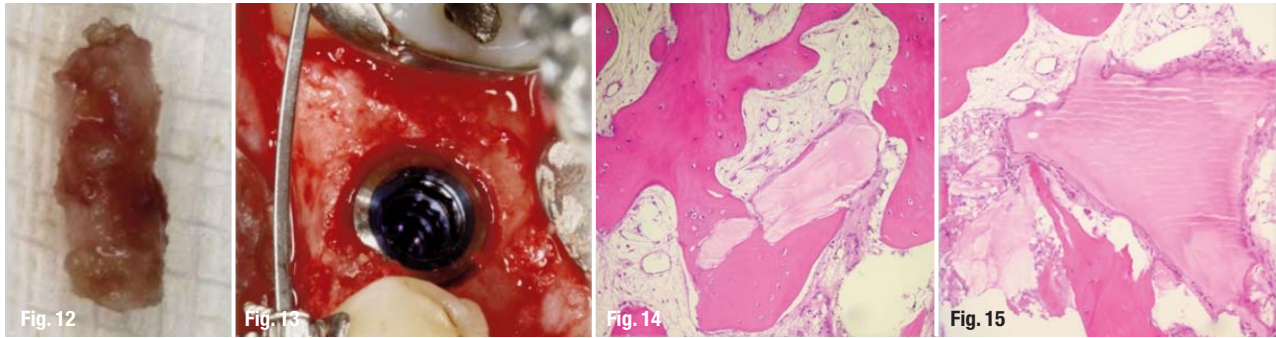


Fig. 13 Implant placement.
Figs. 14 & 15 All samples show new bone formation with the newly formed bone strongly adherent to the bone graft particles.

Surgical treatment

Following administration of local anaesthesia (4% articaine and 0.001% epinephrine), the tooth was elevated and an atraumatic extraction was performed. A full-thickness mucoperiosteal flap was elevated to expose both the labial and the lingual aspects of the alveolar ridge. The extraction socket was then curetted to remove all the soft tissue. A combined two- and three-walled bony defect of 6 and 5 mm and a fenestration of the buccal plate were observed (Figs. 3 & 4). A ridge preservation technique was performed using a xenograft material (a blend of granules of deproteinized bovine bone [90%] and porcine collagen fibres [10%]; Bio-Oss collagen, Geistlich) and a double layer of resorbable collagen membrane (BioGide, Geistlich; Figs. 5 & 6). The flaps were replaced and were sutured with GORE-TEX without obtaining complete socket coverage. Thus, the membrane remained exposed (Fig. 7).

Post-operative care

The patient was given 600 mg ibuprofen every eight hours for the first four days and 500 mg amoxicillin every eight hours for the first seven days and 10 ml 0.20% chlorhexidine gluconate rinses for 30 seconds twice a day (1-0-1) from the day of the operation until day 14 after surgery was prescribed. A toothbrush with extra soft bristles was recommended from the

second week. The patient was advised to avoid chewing on the operated side, and refrain from consuming hot food and drinks for two weeks. A follow-up visit was scheduled for seven days post-treatment, and the sutures were removed after 14 days.

Surgical re-entry for implant placement (at six months following ridge preservation, Figs. 8 & 9)

Following local anaesthesia as described above, a crestal incision was done and a full-thickness flap was raised in preparation for implant placement (Fig. 10). A bone biopsy specimen was harvested in the area previously regenerated using a bone trephine drill. Following the biopsy, the planned implant was placed (Figs. 11–13). The specimen was fixed in a solution of 10% neutral buffered formalin, then dehydrated in ethanol and embedded in methyl-methacrylate resin. Finally, the section was stained with basic fuchsin and toluidine blue, and was observed with an optical microscope at 200x and 400x magnification.

Clinical and histological analysis (Figs. 14 & 15)

Clinically, xenograft particles were well integrated into the alveolus, and the regenerated area was easily distinguishable from the original bone tissue. The new bone formed was firmly attached to the particles of xenograft. The histological analysis revealed no inflammatory response or fibrous encapsulation of par-

	Evaluation time (months)	Membrane	New Bone (%)	Residual Particles (%)	Connetive Tissue (%)	Inflammatory Response
Artzi, 2000	9	No	46,3	30,8	22,9	Minimum
Vence, 2004	4	Collagen	26	16	-	25% sites
Barone, 2008	7	Collagen	35	29	36	No
Cardaropoli, 2008	4	Collagen	-	24,5	-	No
Lee, 2009	4-6	Collagen	23,6	25,4	34,1	Occasional

Table I Histological and histo-morphometric evaluation of the xenograft as an alveolar bone graft material.

ticles of the graft material. All samples showed new bone formation with the newly formed bone strongly adherent to the bone graft particles.

_Discussion

The aim of this case report is to evaluate guided bone regeneration after tooth extraction with a xenograft material. The use of a bone substitute can avoid bone harvesting from a donor site, thus reducing patient discomfort post-operatively.

In a randomised clinical study, Barone et al. (2008) compared extraction-only treatment to ridge preservation with xenograft (cortico-cancellous porcine bone) and collagen membrane. Seven months after tooth extraction, a greater horizontal width reduction of the residual alveolar ridge (8.1 mm versus 6.3 mm) in the extraction-only group was observed. A reduction of vertical ridge height was also observed. These findings were in agreement with previous studies (Iasella et al. 2003). Deproteinized bovine bone has proven to be a highly biocompatible and osteo-conductive material that acts as a natural scaffold for bone formation, and has a low rate of resorption (Carmagnola et al. 2003; Barone et al. 2008).

The absence of inflammatory signs around the xenograft particles suggests that this is a safe and biocompatible biomaterial (Barone et al. 2008). Many studies have demonstrated the absence or a minimal amount of inflammatory infiltrate (Cardaropoli & Cardaropoli 2008), but in a clinical and histological study evaluating ridge preservation with xenografts in humans, Vence et al. (2004) observed some histological inflammation, primarily polymorphonuclear neutrophils in the trabecular spaces, in three of 12 treated sockets, at four months. However, there was no clinical inflammation, and all sites had complete soft-tissue closure by three weeks. The authors suggest that the inflammation may have been related to resorption of the graft particles.

The efficacy of a xenograft as an alveolar bone graft material may be the result of a combination of factors: its osteo-conductive capacity, the increase of mineral content in the grafted area necessary for bone formation and its density in order to provide stability to the graft and to persist for many months (Barone et al. 2008; Artzi et al. 2000).

The histological analysis revealed that in all samples there are residual particles of the xenograft, including studies at nine months (Artzi et al. 2000). According to studies, the volume of residual bone graft material may vary between 16 and 30%. The volume of new bone formation varies between 23 and 46% (Table I).

Histological and histo-morphometric studies have observed that the formation of new bone and the resorption of the xenograft particles is a slow and gradual process. In a nine-year study of a sinus elevation with a xenograft, Traini et al. (2007) observed an increase in bone formation over time, a decrease in the marrow spaces and a slow resorption of the biomaterial. Sartori et al. (2003) presented a case of a sinus augmentation with a xenograft and histo-morphometric evaluation after ten years; he observed that the absorption of the xenograft is slow but constant. He saw a resorption of 3.6% per year for the first two years and a significant decrease in the next eight years, with an average rate of resorption of 0.58% per month.

According to several studies, once the xenograft is in contact with mineralised bone, it acts similarly to the host bone, providing a biologic support for dental implants (Haas et al. 1998). The success of implants placed in regenerated areas of up to 40% of xenograft residual particles seems to be similar to those placed in native bone (Carmagnola et al. 2003).

_Conclusion

The ridge preservation technique limits hard-tissue resorption following tooth extraction. A xenograft with a resorbable collagen membrane has been proven to be a clinically successful means of restoring a bone defect. The histological examination confirmed the presence of newly formed vital bone almost completely surrounding xenograft particles throughout the biopsy samples.

Interviews for candidates to the 3 year Postgraduate Program (2011-14) in Periodontology at Universitat Internacional de Catalunya are opened until the end of April 2011. All candidates must be DDS and fluent in English and Spanish.

Editorial note: A list of references is available from the publisher.

_contact

implants

Prof José Nart

Chairman and Programme Director
Department of Periodontology
Universitat Internacional de Catalunya
C/ Josep Trueta s/n 08195 Sant Cugat del Vallès
(Barcelona), Spain

Tel: +34 93 504 20 30
E-mail: jose@nartperiodoncia.com